



PATIENT

Arthur Meditz

PRESENTING CLINICAL SIGNS

History: Elevated ProBNP.

SPECIES

Feline

BREED

DSH

SEX

Male Neutered

ECHOCARDIOGRAM FINDINGS

2D, m-mode, color flow and doppler imaging is available. The left ventricular wall is irregular with focal septal thickening; however, the remainder appears minimally thickened. There is a mildly hyperechoic endocardium consistent with fibrosis. The papillary muscles are mildly hyperechoic. The left atrium is normal in size. The right atrium is normal in size. The right ventricle appears normal. The mitral valve is normal with trivial MR. No TR. Blood flow through the RVOT is normal. The blood flow through the LVOT is borderline elevated on doppler with a dynamic profile, suggesting an intermittent LVOTO (finding is supported by color flow doppler). No AI. No pleural or pericardial effusion seen. No obvious cardiac tumors

CARDIAC CHART

AGE

6 years

WEIGHT

11.6lbs

INTERPRETED BY

Maggie Machen Lamy,
DVM, DACVIM
(Cardiology)

IMAGING PERFORMED BY

Potomac Mobile
Veterinary Ultrasound

HOSPITAL NAME

Cascades Pet Hospital

REFERRING VET

Dr. Jarrett

INVOICE

29686

DATE

3/17/23

FELINE CARDIAC PARAMETERS	BODY WEIGHT (kg)	HR (BPM)	IVSd (cm) (Moise, Pipers)	LVIDd (cm) (Moise, Pipers)	LWVd (cm) (Moise, Pipers)	FS (%)	EF (%)
NORMAL PARAMETER	-----	150-240	0.35-0.55	<2 (mean 1.5)	3.5-0.55	35-67	80-100
PATIENT	5.3	170	0.70	1.37	0.60	64	94
FELINE CARDIAC PARAMETERS	LA/AO (Boon)	LA/AO HEART BASE (Swe) (Abbott)	LA 2D short axis Base view (cm) (Abbott)		LVOT VEL (m/s)	RVOT VEL (m/s)	E max (m/s)
NORMAL	<1.5	<1.3	<1.2		<1.6	<1.3	<0.9
PATIENT	1.4	1.5	1.3		2.0	1.2	NM

**Note: All measurements based upon multi-modal images and methods. An average value is reported.
Adapted from June Boon, Veterinary Echocardiography, 1998
Abbott J & MacLean H JVIM 2006;20: 111-119, Moise et al. Am J Vet Res 47:1476, 1986. Pipers et al. Am J Vet Res 40:882, 1979.*

INTERPRETATION OF THE FINDINGS & FURTHER RECOMMENDATIONS

The primary abnormality identified is focal septal hypertrophy with LV remodeling, which is concerning for early hypertrophic disease in light of an elevated BNP. The LA is normal which would indicate clinical stability. Serial echocardiography will be necessary to determine progression and clinical significance. Additionally, there is suspicion of a mild LVOT obstruction, which appears intermittent and does not warrant therapy. No additional issues are identified.

Anesthetic risk is considered mild, however judicious IV fluid rates are advised to avoid fluid overload. Additionally, drugs that stimulate heart rate should be avoided unless clinically necessary (glycopyrrolate, atropine). Avoid vasodilators as this may worsen the obstruction. A reasonable protocol includes opioid/benzodiazepine premedication, propofol induction, isoflurane maintenance. Additionally, steroids should be used with caution on older cats, as even a 'normal' geriatric heart can develop evidence of intolerance and fluid retention.

Monitor for any development of clinical signs, including labored breathing or signs of a blood clot (paralysis, neurologic change). Prognosis is guarded prior to assessing for progression.



PATIENT

Arthur Meditz

A recheck echocardiogram is recommended in 6-12 months to screen for any evidence of progression.

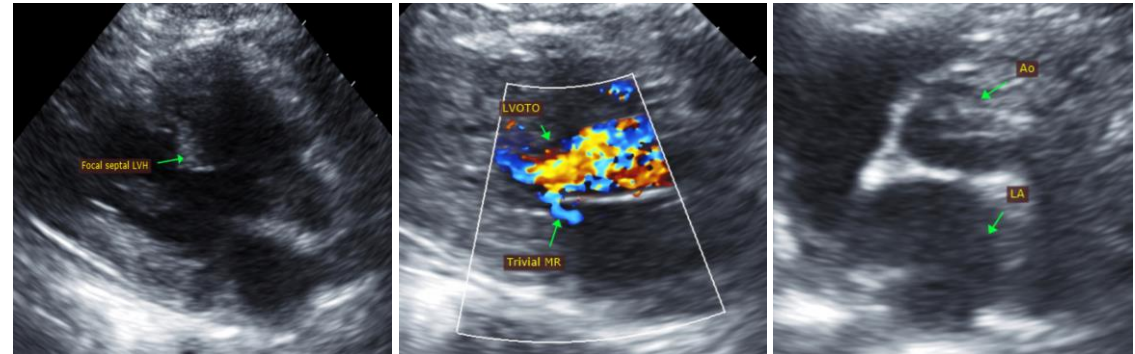
SPECIES

Feline

IMAGES

BREED

DSH



AGE

6 years

The information and recommendations provided are based on the images presented by the referring veterinarian. No evaluation can be communicated regarding pathology that was not visible in the image/video clips provided.

WEIGHT

11.6lbs

Thank you for this referral. This report was generated using transcription software, and minor dictation errors may be present. If the clinical or image interpretation does not parallel your findings or if I can be of any further assistance, please contact me.

INTERPRETED BY

Maggie Machen Lamy,
DVM, DACVIM
(Cardiology)

Maggie Machen Lamy, DVM
Diplomate of the American College of Veterinary Internal Medicine (Cardiology)
info@sonopath.com

IMAGING PERFORMED BY

Potomac Mobile
Veterinary Ultrasound

HOSPITAL NAME

Cascades Pet Hospital

REFERRING VET

Dr. Jarrett

INVOICE

29686

DATE

3/17/23